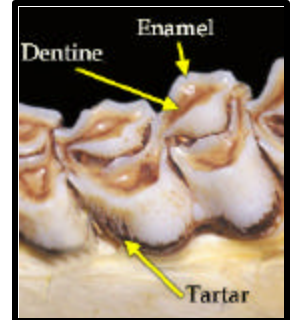


# Aging Deer Jawbones

When aging a deer, only examine the lower jaw bone. Be sure to keep in mind:

- a **cusp** is a point or projection on the chewing surface of a tooth
- the 1<sup>st</sup> three teeth are premolars.
- the last three teeth are molars.
- **Dentine**= brown “stripe” on top of teeth



1. Four to five teeth present (premolars and molars); *Figure A*
  - a. **Fawn** (6 months or less)
2. Six teeth present
  - a. 3<sup>rd</sup> tooth tricuspid; *Figure B*
    - i. **1.5yr old (17mo)**
  - b. 3<sup>rd</sup> tooth bicuspid
    - i. 3<sup>rd</sup> tooth (bicuspid premolar) has no wear or dentine evident and 6<sup>th</sup> tooth (molar) has no wear or dentine evident and may not be fully erupted; *Figure C*
      1. **1.5yr old (18 mo)**
    - ii. 3<sup>rd</sup> tooth (bicuspid premolar) exhibits signs of wear and dentine “stripe” is evident and 6<sup>th</sup> tooth is worn with dentine “stripe” evident; *Figure D*
      1. **2.5+yr old**

